



**HAL**  
open science

## Detection of retinal abnormalities using Smartphone-captured fundus images: A survey

Mohamed Akil, Yaroub Elloumi

► **To cite this version:**

Mohamed Akil, Yaroub Elloumi. Detection of retinal abnormalities using Smartphone-captured fundus images: A survey. Real-Time Image Processing and Deep Learning, Apr 2019, Baltimore, Maryland,, United States. 10.1117/12.2519094 . hal-02121855

**HAL Id: hal-02121855**

**<https://enpc.hal.science/hal-02121855>**

Submitted on 6 May 2019

**HAL** is a multi-disciplinary open access archive for the deposit and dissemination of scientific research documents, whether they are published or not. The documents may come from teaching and research institutions in France or abroad, or from public or private research centers.

L'archive ouverte pluridisciplinaire **HAL**, est destinée au dépôt et à la diffusion de documents scientifiques de niveau recherche, publiés ou non, émanant des établissements d'enseignement et de recherche français ou étrangers, des laboratoires publics ou privés.

# Detection of retinal abnormalities using Smartphone-captured fundus images: A survey

Mohamed Akil<sup>a,\*</sup>, Yaroub Elloumi<sup>a,b,c</sup>

<sup>a</sup>Gaspard Monge Computer Science Laboratory, ESIEE-Paris, University Paris-Est Marne-la-Vallée, France; <sup>b</sup>Medical Technology and Image Processing Laboratory, Faculty of medicine, University of Monastir, Tunisia; <sup>c</sup>ISITCom Hammam-Sousse, University of Sousse, Tunisia.

## ABSTRACT

Several retinal pathologies lead to severe damages that may achieve vision lost. Moreover, some damages require expensive treatment, other ones are irreversible due to the lack of therapies. Therefore, early diagnoses are highly recommended to control ocular diseases. However, early stages of several ocular pathologies lead to the symptoms that cannot be distinguish by the patients. Moreover, ageing population is an important prevalence factor of ocular diseases which is the cases of most industrial counties. Further, this feature involves a lake of mobility which presents a limiting factor to perform periodical eye screening. Those constraints lead to a late of ocular diagnosis and hence important ocular pathology patients are registered. The forecast statistics indicates that affected population will be increased in coming years.

Several devices allowing the capture of the retina have recently been proposed. They are composed by optical lenses which can be snapped on Smartphone, providing fundus images with acceptable quality. Thence, the challenge is to perform automatic ocular pathology detection on Smartphone captured fundus images that achieves higher performance detection while respecting timing constraint with respect to the clinical employment. This paper presents a survey of the Smartphone-captured fundus image quality and the existing methods that use them for retinal structures and abnormalities detection. For this purpose, we first summarize the works that evaluate the Smartphone-captures fundus image quality and their FOV (field-of-view). Then, we report the capability to detect abnormalities and ocular pathologies from those fundus images. Thereafter, we propose a flowchart of processing pipeline of detecting methods from Smartphone captured fundus images and we investigate about the implementation environment required to perform the detection of retinal abnormalities.

**Keywords:** Fundus image, Smartphone captured image, retinal abnormalities, automatic detection

## 1. INTRODUCTION

The number of Smartphone will exceed 3 billion in 2018 [20]. Their processing performance and connectivity allowed to employ them in different professional activity such as the medicine where the appearance of the «mhealth » expression. In particular, many research and engineering works have been interested in the ophthalmology.

In fact, patients of several ocular pathologies outreach hundreds of millions in the world. Many of them are irreversible chronic pathology, such as the Diabetic Retinopathy (DR) and the Aged- macular degeneration (AMD). The ophthalmologists appeal strongly to a periodical screening in order to earlier detection of pathology. However, Ophthalmoscopy requires stationary equipments where patients are constrained to move to have a diagnosis.

Elsewhere, the current rate of ophthalmologists, especially in developed country, is too low which leads to increase the waiting time between the appointment and the consultation. Thus, an important delay was registered in the ocular diagnosis which explain the blindness ration rising.

Therefore, the Smartphone represent a serious alternative solution for retinal screening [4, 5]. Several image capture devices which can be snapped on Smartphone have recently been proposed, with competitive prices. They devices are composed by optical lenses allowing the capture of the retina. The use of these devices is motivated by the significant resolution of images and videos captured by smart phones. The main objective of the project consists at taking advantage of information and communication technologies (ICT) in order to detect ocular pathology.

In this study, we aim to overview the Smartphone captured fundus image employment in the ophthalmology. Thus, we proceed in the beginning to evaluate the quality of the fundus image captured by Smartphone devices and we report their

---

This work was supported by the PHC-UTIQUE 19G1408 Research program.

\* Mohamed.akil@esiee.fr; phone +33 (0)6 73 53 46 89; fax 33(1).60.95.75.75; ligm.u-pem.fr/accueil/

fundus image when used to detect ocular pathologies. In this context, we bring their advantages and inconveniences such as described by the ophthalmologists. Afterwards, we describe the different approach to detect pathologies from the fundus image capture to the result displaying.

## 2. SMARTPHONE CAPTURED FUNDUS IMAGES EVALUATION

### 2.1 Quality of Smartphone-captured fundus images

Several works are interested to the quality of fundus image captured by Smartphone, with respect to the clinical employment. The work described in [32] describes an experimentation that evaluates the D-EYE lens captured fundus images with respect to the direct ophthalmoscope ones. A rating between 0 and 5 is asked from 25 patients to each picture. The average ratings are 3 and 4.08 respectively for direct ophthalmoscope and D-EYE digital ophthalmoscope. 92% of students reclaim their preference to use D-EYE [9, 10] despite the direct ophthalmoscope. In [21], ophthalmologists deduced that Smartphone captured fundus image are readable with an average between 86% and 100%, and have an accepted quality in 93%-100%. However, Darma et al. [26] indicate that a good image quality is still prerequisite. Jin et al. [39] were summarized a qualitative comparison study between portable and tabletop fundus camera by grading 400 fundus images in each categories. The ophthalmologists assign excellent overall quality about 63% and 70.75% and inadequate quality about 4.75% and 3.25% respectively for portable and tabletop camera.

### 2.2 Field Of View (FOV) of Smartphone capture devices :

Image capture device consists always to a lens snapped in a Smartphone that allows embedded camera to capture fundus images. These devices are varied in terms of FOVs, ever for mydriatic or non-mydriatic mode. Several lenses insure an FOV between 45° and 50° which are similar to the direct ophthalmoscope, such as the Volk-N-View and Welch Allyn Panoptic Ophthalmoscope [2]. These devices lead to provide fundus image containing all retinal structures such as the blood vessel tree, the macula, etc, as shown in figure 1. (b). Others ones propose a FOV less than 45°, such as Paxos Scope fundus imaging [1] and the D-EYE where corresponding fundus image is illustrated in figure 1.(a). Indeed, automatic ocular pathology detection methods are based on retinal structure localization in order to deduce lesions shapes. Thus, every processing should verify at first if retinal structures that correspond to the pathology are well modeled. In contrast, no detection can be performed.

We distinguish that approach is proposed to capture multi-field fundus images. In [37], a three single-shot images was performed and then merged in order to achieve an FOV equal to 92°, as shown in figure 1.(c). In [34], five 50° FOV images are captured in rapid sequence where orientation are respectively of the central, inferior, superior, nasal, and temporal retina. Therefore, the merged images provide approximately 100° wide-field fundus image, where fundus image is illustrated in [34]. Tolsak et al. [31] propose to overlay lenses in order to capture several images in a single-shot image. Thereafter, the images were merged to provide a 152° view. In [37], the authors pretend that a real time 180° FOV image providing can be achieved through a collaborative work based on ophthalmologist experience and improved montage data processing. However, wide-field of view employment is limited by the processing execution time. The method related in [34] indicates that five montages of images in iPhone 5 having a resolution equal to 52.3 pixels/retinal degree require approximately 5 minutes.

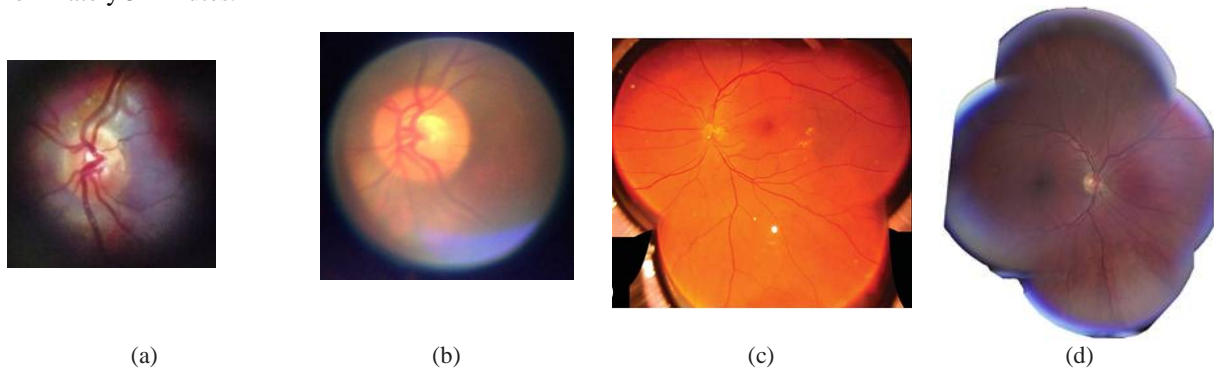


Figure 1. Smartphone-captured fundus images with different FOV: (a) captured with D-EYE; (b) captured Welch Allyn Panoptic Ophthalmoscope; (c) captured with ophthalmoscopy lens-based Smartphone fundus cameras [17]; (d) captured with CellScope [34]

### 3. SMARTPHONE CAPTURED FUNDUS IMAGES FOR OCULAR DISEASE DETECTION

#### 3.1 Smartphone-captured fundus image capability

Several works are proposed to evaluate the quality of the Smartphone-captured fundus images, and the capability to deduce ocular diseases from them. The work described in [22] studied the agreement between clinical ophthalmic examination and Smartphone-assisted acquisition using Paxos Scope lens. It deduces that the smart phoned-based fundus camera fundus represents a screening tool to sufficiently identify patients with Diabetic Retinopathy (DR). Russo et al. [23] aim to estimate the Vertical Cup-to-Disc Ratio using both Smartphone ophthalmoscopy using the D-EYE lens and slit-lamp biomicroscopy where the agreement leads to a correspondence parameter «Kappa » is equal to 0.63. The work proposed by Thomas et al. [29] indicated that Tele-glaucoma allows achieving specificity and a sensibility respectively equal to 79% and 83%. Ryan et al. [24] aim to evaluate the DR detection using Smartphone fundus photography with respect to non-mydratic and 7-field mydratic fundus photography. They deduce that both Smartphone and non-mydratic fundus photography are able to detect DR, even the non-mydratic one is more sensitive.

The same objective is targeted in the work described in [25] that compares the “fundus on phone’ (FOP) and 7-standard field digital retinal photography to detect DR severity. Even the poor quality in some fundus images captured by FOP images, this study does not report a signification difference on the detection performance where the correspondence metric «Kappa » between both evaluations is equal to 90%.The work described in [27] evaluates the capability of the D-Eye device to allow detecting the DR. The authors report that fundus image quality is not enough higher to detection the DR, but indicates that the technological advances will improve the Smartphone fundus photography capabilities.

In [28], the reported study compares the ocular pathology screening feasibility between Smartphone, small optical device and traditional ocular fundus examination. In this context, all patients were examined by a medical student (observer 1) using both a traditional ophthalmoscope and the D-EYE lens. Thereafter, D-EYE captured fundus images were independently analyzed by an ophthalmologist (observer 2). Both observers affected a quantitative score between 0 and 5 respectively to hemorrhages, exudates and papillary edema. The study deduced a good concordance between traditional ophthalmoscope and the D-EYE lens where k coefficient value is between 0.66 to 0.77 for hemorrhages and exudates, and between 0.89 and 0.90 for the papilledema, which are diabetic retinopathy lesions.

Table 1. Characteristics and performance of ocular diseases detection from Smartphone-captured fundus image

Works	Pathologies	Fundus image number	Performance - Evaluation	Capture device
Toy et al.[22]	moderate nonproliferative &Worse diabetic retinopathy	100	91% sensitivity 99% specificity 95% positive predictive value 98% negative	Paxos Scope
Russo et al. [23]	Vertical Cup-to-Disc Ratio (glaucoma)	107 eyes	95% sensitivity 95% specificity 63 % Kappa (k)	D-EYE
Ryan et al. [24]	DR	--	With 7-field mydratic: Sensitivity 95% Specificity 94% Non-mydratic: Sensitivity 95% Specificity 95%	--
Rajalakshmi et al. [25]	DR	--	Sensitivity 92.7 % Specificity 98.4 % Kappa ( κ) = 0.90	(FOP) camera
Micheletti et al. [27]	DR	240 eyes	--	D-Eye
Muiesan et al. [28]	hemorrhages exudates papiledema	52 patients (104 fundus images)	Hemorrhages: 0.795 Exudates: 0.822 – 0.878 Papiledema: 0.815 – 0.804	D-Eye
thomas et al. [29]	glaucoma		specificity 79% sensibility 83%	
Jin et al. [39]	DR AMD	--	P>0.05	MiisDEC 200

### 3.2 Advantages of Smartphone fundus image capturing for diseases detection

The ophthalmologists indicate that capturing fundus images using Smartphone offers several advantages. Aside easier acquisition [21,25], such device allows saving capture time, where the work described in [25] affirms that acquisition time per eye is less than 1 minute while [23] indicates that requires  $12.8 \pm 3.2$ s. Another main advantage corresponds to the reduced cost of the capture device [21, 22] which requires a lens integrated in plastic adapter which is snapped on owned Smartphone with free or low-cost Smartphone software. Moreover, the autofocus and the zooming option facilitate the acquisition and lead to provide a fundus image good quality [25]. With data capability, connectivity and portability, the capture devices represent promising tools for screening fundus images and diagnosing ocular diseases, which can be employed for tele-ophthalmology [21, 22, 25, 27]. The captured images and videos may be sent to ophthalmologists to be saved and interpreted.

Such system is more and more required due to the rise of several prevalence of ocular diseases [21, 27], where annual ophthalmic examinations may increase from 50% to 70% in diabetic patients [21]. Therefore, the tele-ophthalmology leads to bring the early diagnosis and hence rising the global visual health with respect to the aim of VISION 2020 (“VISION 2020 [21] is a global initiative of the International Agency for the Prevention of Blindness (IAPB)”, <https://www.ao.org/vision-2020>).

As indicated in [21], 88% of patients reclaimed their satisfaction and preference to the tele-ophthalmology due to the convenience, visualization of their retina and time saving. The work described in [25] related that participants distinguish a comfortable acquisition compared to the clinical fundus capture due the lower LED light intensity in the Smartphone. However, the tele-ophthalmology system should guarantee the patient privacy, data confidentiality and security [27].

### 3.3 Inconvenience of Smartphone fundus image capturing

Several works related some lacks in the Smartphone captured fundus images. In [28], the papilledema appears slightly overestimated due to the brightness and the blurring of optic disc. Also, the work described in [23] indicates that the vertical Cup Disc ratio is overestimated which is due to a higher brightness of the cup compared to the rim. This feature should be taking into account by the ophthalmologist. Further, this work suggests considering other glaucoma assessment such as the cup shape and the vessel tree to enhance the detection. In [25], the Smartphone captured fundus images have a reasonably good quality despite a deduced poor clarity which leads to missing some lesions and new vessels in Proliferative Diabetic Retinopathy (PDR). Likewise, a worse image quality of the hand-held fundus photography device compared to the standard fundus photography was detected [26]. Moreover, the work described in [24] indicated some limitations to detect lesions such as fine neovascularization or macular edema.

In contrast, several works [26, 24, 27] indicate that the permanent rising of quality Smartphone images and acquisition standardization can make Smartphone systems clinically more useful. In addition, collaboration between ophthalmologists, physicians and software researchers is required in order to improve image quality, rely the data reliability and optimize the pathology detection process [22, 27].

## 4. RETINAL ABNORMALITY DETECTION IN FUNDUS IMAGES

### 4.1 Flowchart of Retinal abnormality detection

The main objective of ophthalmoscopy is to detect retinal abnormalities and ocular pathologies. The Smartphone-captured fundus images are always captured through optical lenses and saved on the Smartphone that snap it. For the detection step, several works benefit from the Smartphone connectivity in order to send the fundus image to a cloud platform. In this case, we distinguish two approaches of tele-ophthalmology. The first one consists at forwarding fundus image to ophthalmologists in order to outlining the abnormalities and/or the ocular pathologies deduced [39]. Thereafter, the results are returned to the subjects. In the second approach, an intelligent software tool is integrated on the cloud-platform which insures an automatic detection [11, 13, 19]. Another approach consists at performing the detection on the Smartphone as an all-in-one device for ophthalmology mobile computer-aided-system [12, 18].

### 4.2 Automatic method for Retinal abnormality detection

#### 4.2.1. preprocessing

The work described in [11] applies a convolution filter to make images more consistent and smoother, with a size equal to 525. The work described in [17] proposed a pipeline where the first step leads to enhance the retina by deblurring the Smartphone-captured fundus image. The next step involves contrast balancing using the CLAHE approach. The next

component consists of apply the circular Hough transform is employed in the pipeline to detect circular patterns. In [18], authors note that Smartphone captured fundus images often have a non-balanced contrast. A light leakage normally occurs which leads to fundus and background having a similar contrast. To avoid this problem, the Contrast Limited Adaptive Histogram Equalization (CLAHE) approach is applied to the blue component of the fundus image. Moreover, the eye fundus size and location differ from one image to the other due to the handholding of a Smartphone. Thus, no predefined binary mask can be applied to outline the fundus. Hence, Elloumi et al. [18] employ the roundness to outline the fundus. For this purpose, the image is dilated in order to dispose blood vessels. Then, the circular Hough transform is applied to detect the circular pattern of the fundus. A radius range is assigned to avoid detecting the ONH instead of the fundus. This way, the radius and center indices represent the parameters of the binary mask applied to outline the fundus. The work described in [8] propose an algorithm to assess image quality using a human vision system based evaluation.

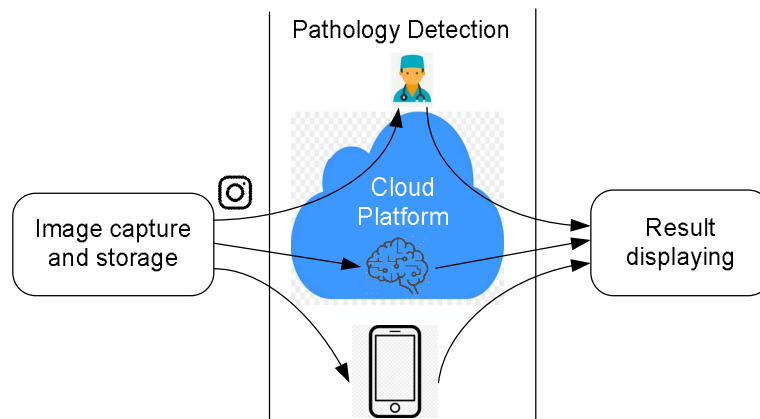


Figure 2. Flowchart of Retinal abnormality detection

Otherwise, the wide-field requires a preprocessing step that consists of merging fundus images, which consists at translating, rotating and skewing the border image with respect to the central one. For this purpose, the preprocessing brings to correct optical distortion, reframe and figure out the neighboring each image.

#### 4.2.2. Detection processing

In [11], the main objective consists at screening the diabetic retinopathy using a neural network with mobileNets model. First, the images in the dataset are resized from 492823264 to 2562256 pixels. The neural network has 28 convolution layers. A pre-trained network is utilized which was trained with millions of images from ImageNet dataset. The work described in [12] implements an unsupervised vessel segmentation algorithm by using parallel processing and efficient resource sharing, achieving real-time performance.

In [13], an intelligent ocular disease assessment engine is proposed. It contains a rich suite of algorithms that analyses the risk of glaucoma, AMD, DR and pathological myopia. For glaucoma detection, a quantitative measure is generated through intelligent analysis of 2D retinal fundus image. The OD is first segmented in order to deduce the disease. For the AMD assessment, the OD is detected as a reference point of the macula, which allows detecting automatically the presence of drusens. In [6], the authors propose to employ a DR screening software, called “EyeArt”, to detect DR and classify the DR severity. This tool is cloud based software that performs artificial intelligent techniques to detect DR lesions. The work described in [15] implements a diabetic feature detection approach proposed in [16], on Android smartphones. The app is compared with retinograph-captured fundus images where the detection accuracy is about 87%. In [11], the “MobileNets” CNN is configured to classify smartphone captured fundus images on two classes (Dr or no DR) where final accuracy is about 73%.

## 5. DISCUSSION

We reported in the first section that several image capture devices were recently proposed where images were evaluated in different works. However, we distinguish a lack of studies that aim to compare fundus images captured with different devices. Further, the work proposed in [30] verify the safety of the luminosity of an optical lens, which respect to the ISO15004-2.2 in terms of maximal authorized magnitude limits of thermal and photochemical hazards. Such validation should be performed for all handheld ophthalmoscopy.

In addition, each work evaluating Smartphone-captured fundus images proposes its own capturing and testing methodology. We think that a normalized methodology should be proposed in order to insure a credible validation. In this context, Khanamiri et al. [33] propose well-defined steps for Smartphone ophthalmoscopy in order to record a higher quality image. This method can be generalized to take into account the optical characteristics of each dispositive in terms of superposed lenses, light reflex ion and distance to the iris.

The captured fundus image FOV varied from 25° to 152°, to the best of our knowledge, no work has been reported that studies relation between the FOV and the ocular pathology detection. Moreover, we think that automatic detection method principle should be configured in terms of FOV fundus images. Further, even multi-field images are a promising, but the processing execution time is a limiting factor to employ it when detect ocular pathology, especially with the permanent rise of camera resolution. The number of merged images can be modified with respect to the retinal structures that we aim to detect. Moreover, it seems important to appeal higher performance computing techniques in order to reduce execution time.

The section 3 described the flowchart of automatic methods for Retinal abnormality detection. Based on image quality, it seems important to propose a preprocessing step in order to avoid noise, blur and non-equalized contrast due to the handheld capture process. Several works occur to the tele-ophthalmology in order to automatically scheduling the fundus images to experts for diagnosis. However, this approach is limited by the reduced ophthalmologists available for detection, either in industrialized or non-industrialized countries. Otherwise, few works propose to implement a detection approach on Smartphone, which leads to an “all-in-one” mobile system for abnormality detection. Based on the improvement of Smartphone processing performance, the actual challenge consists at implementing machine learning methods on handheld devices.

## 6. CONCLUSION :

This paper presents an overview the Smartphone captured fundus image employment in ophthalmology. Thus, we studied the quality of the fundus image captured by Smartphone devices. Thereafter, we summarized their capability to allowing ocular pathology detection. The third section is focalized on the flowchart of diagnosis based on Smartphone captured fundus images where we distinguish three different approaches. Then, we reported the automatic method applied to retinal structure and abnormality detection where we synthesized the processing principle even on the preprocessing or on the detection steps.

This study in enclose by a discussion where we report the requirement of normalized approach for fundus image capture, a well-defined preprocessing to fundus image enhancement and the implementation of machine learning on Smartphone to insure a local detection.

## REFERENCES

- [1] Sharma, A., “Emerging Simplified Retinal Imaging”, Pathogenesis and Imaging, Dev Ophthalmol. Basel, Karger, pp. 56–62, vol 60, 2017. DOI: 10.1159/000459690.
- [2] Besenczi, R., Szitha, K., Harangi, B., Csutak, A. and Hajdu, A., “Automatic optic disc and optic cup detection in retinal images acquired by mobile phone”, 9<sup>th</sup> Int. Symp. on Image and Signal Processing and Analysis (ISPA), Zagreb, Croatia, 2015. DOI: 10.1109/ISPA.2015.7306057.
- [3] Newman-Casey, P.A.,” Portable non-mydratic device closes gap on tele-glaucoma screening”, 2016, Modern Medicine Feature Articles, Modern Medicine Feature Articles, Ophthalmology, 2016.
- [4] Mamtora S., Sandinha, Amritha Ajith M. T., Song A. and Steel D. H. W., “Smartphone ophthalmoscopy: a potential replacement for the direct ophthalmoscope”, Eye, 32(11):1766-1771, 2018 . DOI: <https://doi.org/10.1038/s41433-018-0177-1>.
- [5] Devi S. S., Ramachandran K.I., and Sharma A., “Retinal Vasculature Segmentation in Smartphone Ophthalmoscope Images”, 7th World Congress on Bioengineering, IFMBE Proceedings, 52, 2015. DOI: [https://doi.org/10.1007/978-3-319-19452-3\\_18](https://doi.org/10.1007/978-3-319-19452-3_18).
- [6] Ramachandran Rajalakshmi, Radhakrishnan Subashini, Ranjit Mohan Anjana, Viswanathan Mohan, “Automated diabetic retinopathy detection in smartphone-based fundus photography using artificial intelligence”, Eye, **32**, pages1138–1144 (2018). DOI: <https://doi.org/10.1038/s41433-018-0064-9>.
- [7] Blanckenberg M., Worst C. and Scheffer C., “Development of a Mobile Phone Based Ophthalmoscope for Telemedicine”, Proceedings of the IEEE Engineering in Medicine and Biology Conference, Massachusetts, 5236-5239, 2011. DOI : 10.1109/IEMBS.2011.6091295.

- [8] Wang S., Jin K., Lu H., Cheng C., Ye J. and Qian D., “Human visual system-based fundus image quality assessment of portable fundus camera photographs”, *IEEE Trans. on Medical Imaging*, 35:1046–1055, April 2016. DOI: 10.1109/TMI.2015.2506902.
- [9] Russo A., Morescalchi F., Costagliola C., Delcassi L., and Semeraro F., “A Novel Device to Exploit the Smartphone Camera for Fundus Photography”, *Journal of Ophthalmology*, Article ID 823139, 2015.
- [10] Russo A., Morescalchi F., Costagliola C., Delcassi L., and Semeraro F., “Comparison of Smartphone Ophthalmoscopy With Slit-Lamp Biomicroscopy for Grading Diabetic Retinopathy”, *American Journal of Ophthalmology*, 159:360-364, February 2015.
- [11] Suriyal S., Druzgalski C., Gautam K., “Mobile Assisted Diabetic Retinopathy Detection using Deep Neural Network”, 2018 Global Medical Engineering physics exchanges (GMEPE), Porto, Portugal, March, 2018. DOI: 10.1109/GMEPE-PAHCE.2018.8400760.
- [12] Koukounis D., Ttofis C., Papadopoulos A. and Theocharides T., “A high performance hardware architecture for portable, low-power retinal vessel segmentation”, *INTEGRATION journal*, Volume 47, Issue 3, June 2014, Pages 377-386, 2014. DOI: <https://doi.org/10.1016/j.vlsi.2013.11.005>.
- [13] Yin F., Lee B.H., Yow A.P., Quan Y. and Wong D.W.K., “Automatic Ocular Disease Screening and Monitoring Using a Hybrid Cloud System”, 2016 IEEE International Conference on Internet of Things (iThings), pp 2663-268, 2017. DOI: 10.1109/iThings-GreenCom-CPSCoM-SmartData.2016.68.
- [14] kaur J., kaur R., “Low cost cataract detection system using smart phone”, 2015 International Conference on Green Computing and Internet of Things (ICGCIoT), Noida, India, page : 1607-1609, 2015.
- [15] Bourouis A., Feham M., Hossain M.A., Zhang L., “An intelligent mobile based decision support system for retinal disease diagnosis”, *Decision Support Systems*, 59, 341–350, 2014. <https://doi.org/10.1016/j.dss.2014.01.005>.
- [16] Gardner G.G., Keating D., Williamson T.H., Elliott A.T., “Automatic detection of diabetic retinopathy using an artificial neural network: a screening tool”, *Br. J. Ophthalmol.* vol. 80, 940–944, 1996.
- [17] Elloumi Y., Akil M. and Kehtarnavaz N., “A Computationally Efficient Retina Detection and Enhancement Image Processing Pipeline for Smartphone-Captured Fundus Images”, *Journal of Multimedia Information System*.
- [18] Elloumi Y., Akil M. and Kehtarnavaz N., “A mobile computer aided system for optic nerve head detection”, *Computer Methods and Programs in Biomedicine (CMPB)*, Vol. 162, August 2018, pages 139-148, DOI: <https://doi.org/10.1016/j.cmpb.2018.05.004>
- [19] <http://www.eyenuk.com/eyemark.html>
- [20] <https://venturebeat.com/2018/09/11/newzoo-smartphone-users-will-top-3-billion-in-2018-hit-3-8-billion-by-2021/>
- [21] Mohammadpour M., Heidari Z., Mirghorbani M. and Hashemi H., “Smartphones, tele-ophthalmology, and VISION 2020”, *Int J Ophthalmol*, 2017, Vol. 10, No. 12. doi: 10.18240/ijo.2017.12.19.
- [22] Toy B.C., Myung D.J., He L., Pan C. K., Chang R. T., Polkinhorne A., Merrell D., Foster D., and Blumenkranz M. S., “Smartphone-Based Dilated fundus Photography And Near Visual Acuity testing as Inexpensive Screening Tools to Detect Referral Warranted Diabetic Eye Disease”, *Retina*, 36(5):1000-8, 2016. doi:10.1097/IAE.0000000000000955.
- [23] Russo A., Mapham W., Turano R., Costagliola C., Morescalchi F., Scaroni N., and Semeraro F., “Comparison of Smartphone Ophthalmoscopy With SlitLamp Biomicroscopy for Grading Vertical Cup-to-Disc Ratio”, *J Glaucoma*, Volume 25, Number 9, September 2016. doi: 10.1097/IJG.0000000000000499.
- [24] Ryan M. E., Rajalakshmi R., Prathiba V., Anjana R. M., Ranjani H., Narayan K.M.V., Olsen T.W., Mohan V., Ward L.A., Lynn M. J. and Hendrick A. M., “Comparison Among Methods of Retinopathy Assessment (CAMRA) Study”, *Ophthalmology*, 122(10):2038-43, 2015. DOI: 10.1016/j.ophtha.2015.06.011.
- [25] Rajalakshmi R., Arulmalar S., Usha M., Prathiba V., Kareemuddin K.S., Anjana R.M. and Mohan V., “Validation of Smartphone Based Retinal Photography for Diabetic Retinopathy Screening”, *PLoS ONE* 10(9): e0138285. doi: 10.1371/journal.pone.0138285
- [27] Micheletti J. M., Hendrick A. M., Khan F. N., Ziemer D. C. and Pasquel F. J., “Current and Next Generation Portable Screening Devices for Diabetic Retinopathy”, *Journal of Diabetes Science and Technology* 2016, Vol. 10(2) 295–300. doi: 10.1177/1932296816629158.
- [28] Muiesan M. L., Salvetti M., Paini A., Riviera M., Pintossi C., Bertacchini F., Colonetti E., Agabiti-Rosei C., Poli M., Semeraro F., Agabiti-Rosei E., and Russo A., “Ocular fundus photography with a smartphone device in acute hypertension”, *Journal of Hypertension*, 35:1660–1665, Volume 35, Number 8, August 2017. doi: 10.1097/HJH.0000000000001354.
- [29] Thomas S.M., Jeyaraman M.M., Hodge W.G., Hutnik C., Costella J., Malvankar-Mehta M.S., “The effectiveness of teleglaucoma versus inpatient examination for glaucoma screening: a systematic review and meta-analysis”, *PLoS One* 2014;9(12):e113779.
- [30] Hong S.C., Wynn-Williams G. and Wilson G., “Safety of iPhone retinal photography”, *Journal of medical engineering and technology*, 41(3):165-169, 2017. DOI: 10.1080/03091902.2016.1264491.
- [31] Toslak D., Thapa D., Chen Y., Erol M.K., Chan R. V. P., AND Yao X., “Trans-palpebral illumination: an approach for wide-angle fundus photography without the need for pupil dilation”, *Optics Letters*, Vol. 41, No. 12, June 2016.
- [32] Wu A.R., Fouzdar-Jain S., Suh D. W., “Comparison Study of Funduscopy Examination Using a Smartphone-Based Digital Ophthalmoscope and the Direct Ophthalmoscope”, *Journal of Pediatric Ophthalmology & Strabismus*, Vol. 55, No. 3, 2018.



- [33] Khanamiri H. N., Nakatsuka A., El-Annan J., "Smartphone Fundus Photography", *Journal of Visualized Experiments*, 125, e55958, July 2017.
- [34] Kim T. N., Myers F., Reber C., Lory P.J., Loumou P., Webster D., Echanique C., Li P., Davila J. R., Maamari R.N., Switz N. A., Keenan J., Woodward M.A., Paulus Y. M., Margolis T. and Fletcher D. A., "A Smartphone-Based Tool for Rapid, Portable, and Automated Wide-Field Retinal Imaging", *TVST*, 2018, Vol. 7, No. 5, Article 21.
- [35] Sharma A., Subramaniam S. D., Ramachandran K., Lakshmikanthan C., Krishna S., Sundaramoorthy S.K., "Smartphone-based fundus camera device (Mii ret cam) and technique with ability to image peripheral retina", *Eur J Ophthalmol.*, 26 (2): 142-144, 2016.
- [36] Behera S. and Pradhan A., "MII Ret Cam: A Boon towards Retinal Disease Imaging and Documentation", *J Clin. Exp. Ophthalmol.*, ISSN:2155-9570, Volume 8, Issue 5, 1000685.
- [37] Toslak D., Ayata A., Liu C., Erol M.K., Yao X., "Wide-field smartphone fundus video camera based on miniaturized indirect ophthalmoscopy", *Retina*, 38(2):438-441, 2018. DOI: 10.1097/IAE.0000000000001888.
- [38] Fenner B.J., Raymond L. M. , Lam W.C., Tan G. S. W., Cheung G. C. M., "Advances in Retinal Imaging and Applications in Diabetic Retinopathy Screening: A Review", *Ophthalmol. Ther.*. DOI: <https://doi.org/10.1007/s40123-018-0153-7>
- [39] Jin K., Lu H., Su Z., Cheng C., Ye J. and Qian D., "Telemedicine screening of retinal diseases with a handheld portable non-mydriatic fundus camera", *BMC Ophthalmology*, 17:89, 2017. DOI: 10.1186/s12886-017-0484-5.
- [40] Rajalakshmi R., Subashini R., Anjana R.M. and Mohan V., "Automated diabetic retinopathy detection in smartphone-based fundus photography using artificial intelligence", *Eye*, 32(6):1138-1144, Jun 2018. DOI: <https://doi.org/10.1038/s41433-018-0064-9>.